


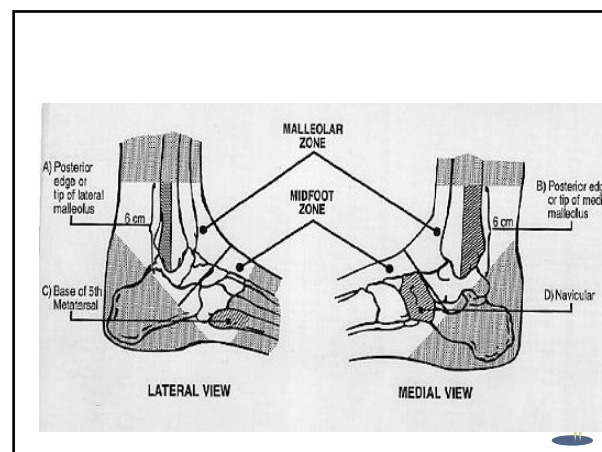
ThinkAskLearn
Health Professional Education

Upper Limb Injuries

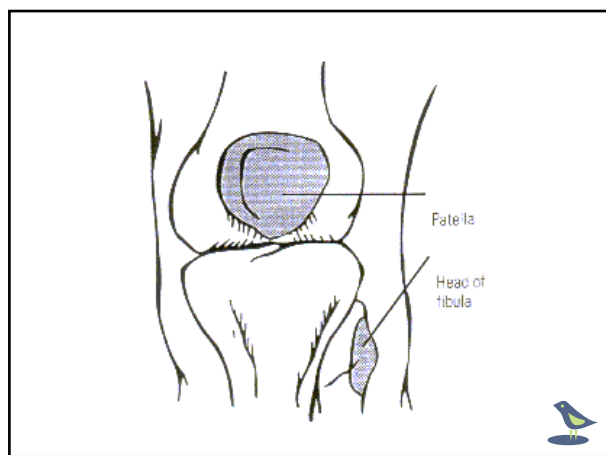
David Corkill
Emergency Nurse Educator
MEmergN, MAdvPrac (Hth Prof Edu), BN, Dip App Sc
www.thinkasklearn.com.au



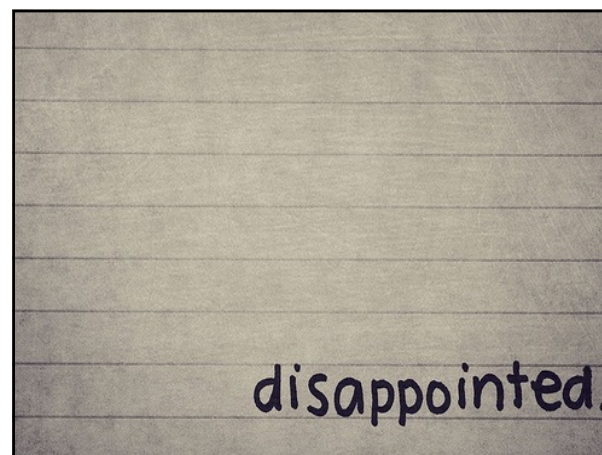
1



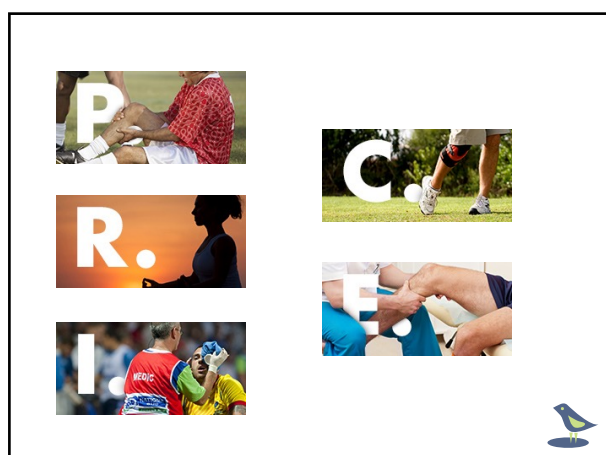
2



3




4



5

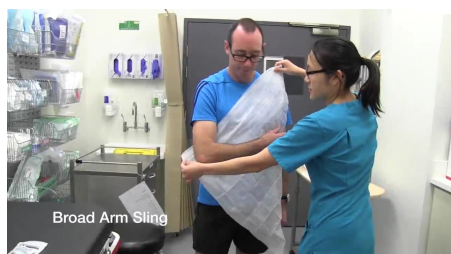AMPLET

- **A**llergies
- **M**edications
- **P**ast History
- **L**ast ate
- **E**nvironment
- **T**etanus



6

Slings



Broad Arm Sling



7

Limbo Cast Covers



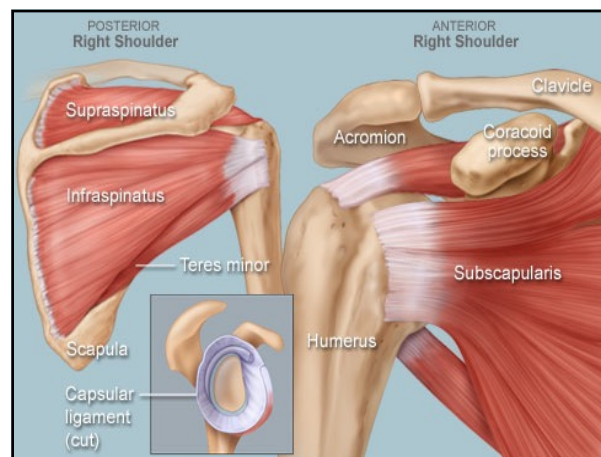
8

The Shoulder

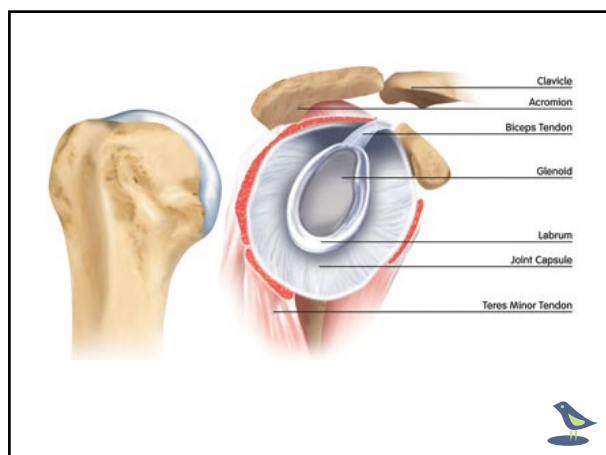
•16 y.o. Male – playing football was tackled and fell to the ground – directly onto right shoulder - c/o pain



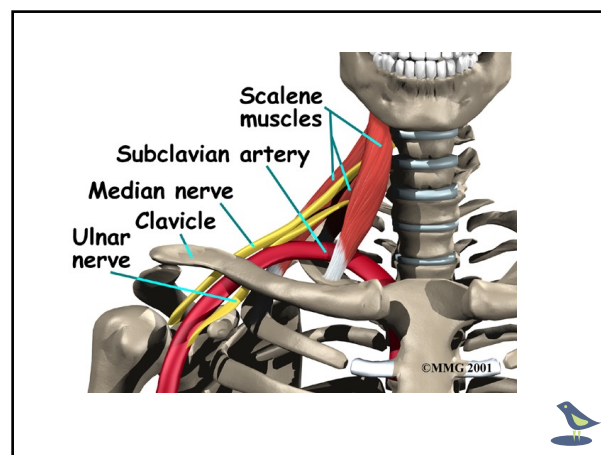
9



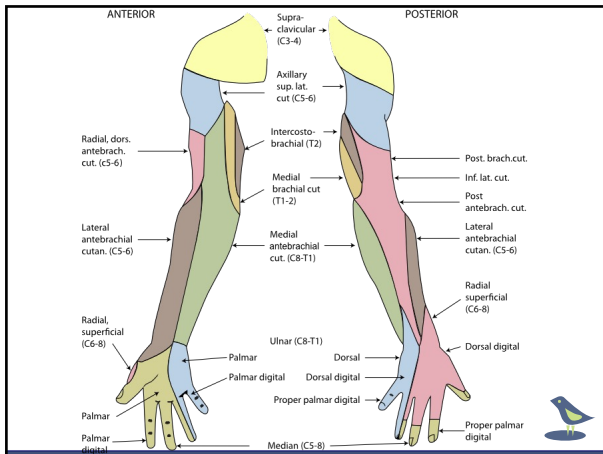
10



11



12

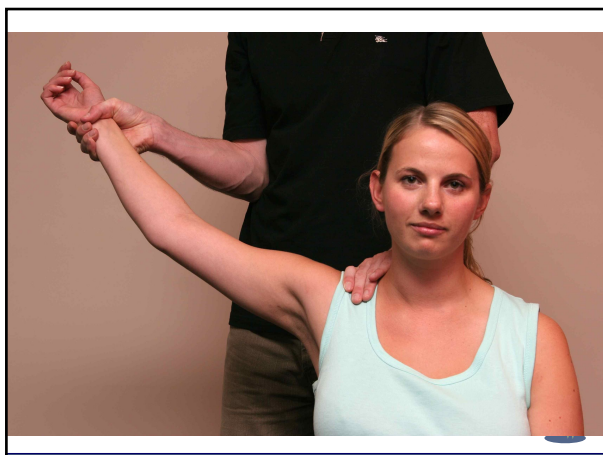


13

Shoulder Dislocations

- 99% Anterior Dislocations
- Usually abducted and externally rotated
- May have external, posterior force applied

14

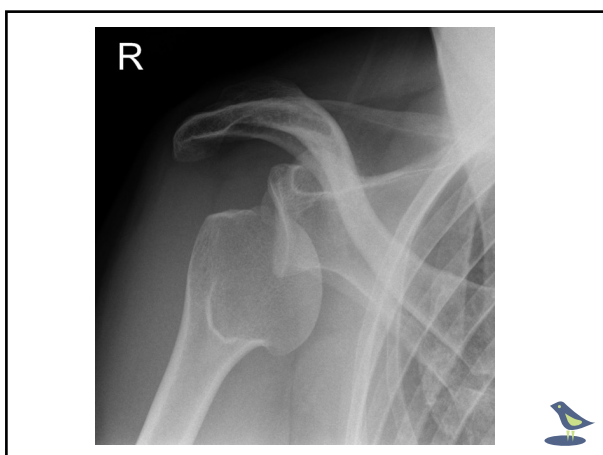

15

Shoulder Dislocations

- 99% Anterior Dislocations
- Usually abducted and externally rotated
- May have external, posterior force applied
- Fall
- Usually male, under 30,
- 1% Posterior Dislocation
 - Seizure
 - MVA Seatbelt
 - Electrocution

16



17

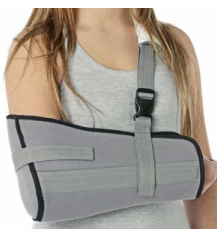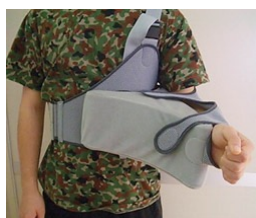Presentation

- Usually arm abducted across chest
- Anterior fullness
- Loss of deltoid contour
- Extreme pain in first instance
- Usually good history
- Neuro- Tingling over deltoid

About 54% of presentations to the ED were initial dislocations

18

Post Reduction Management



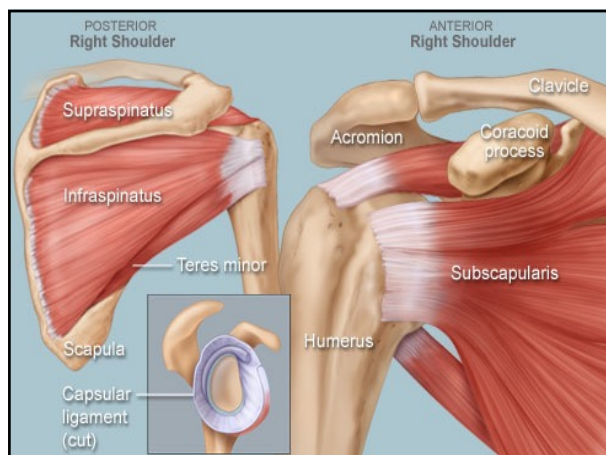
19

AC Joint Dislocation

- Not really a dislocation but is a tear of the acromioclavicular ligament



20



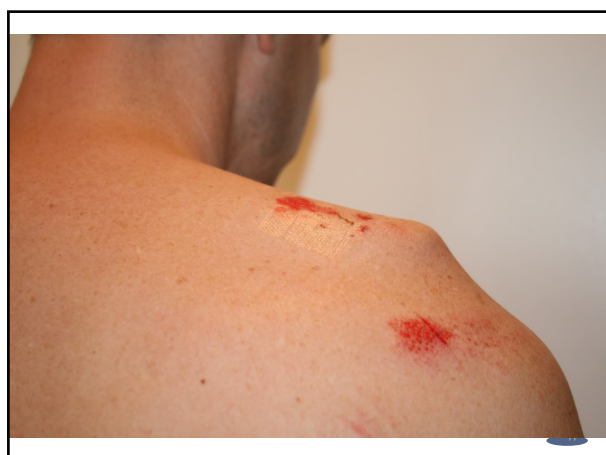21

AC Joint Dislocation

- Not really a dislocation but is a tear of the acromioclavicular ligament
- Results from fall onto point of shoulder
- Prominent outer end of clavicle
- Drooping of shoulder



22



23

AC Joint Dislocation

- Not really a dislocation but is a tear of the acromioclavicular ligament
- Results from fall onto point of shoulder
- Prominent outer end of clavicle
- Drooping of shoulder
- Pain on movement
- Localised tenderness
- Supporting shoulder



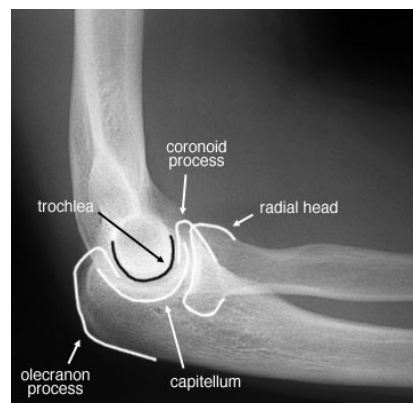24

Management

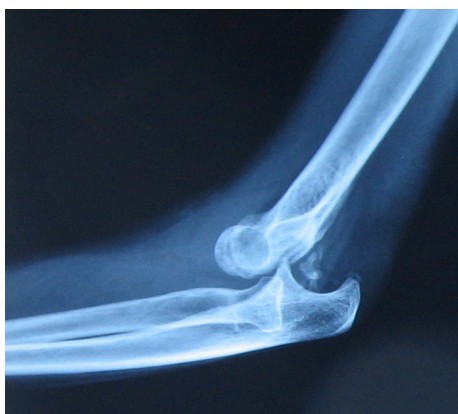- Stand Patient
- Assess both shoulders
- Local tenderness is always present
- Trip to Hospital
 - Analgesia
 - Xray -both shoulders to compare AP
- Broad arm sling and Ice to shoulder
- Gross disruption may require OT (screw clavicle to coracoid process)



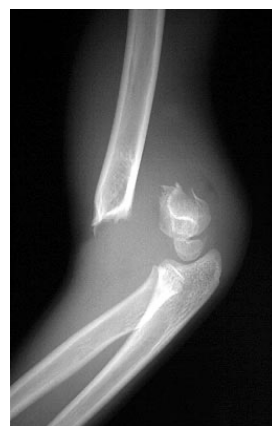25



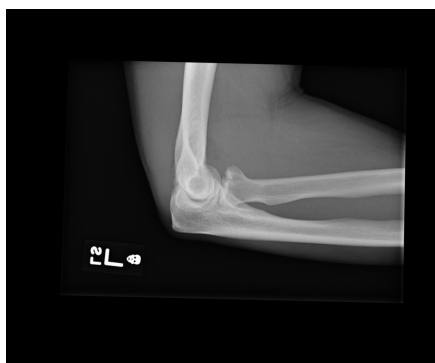26




27



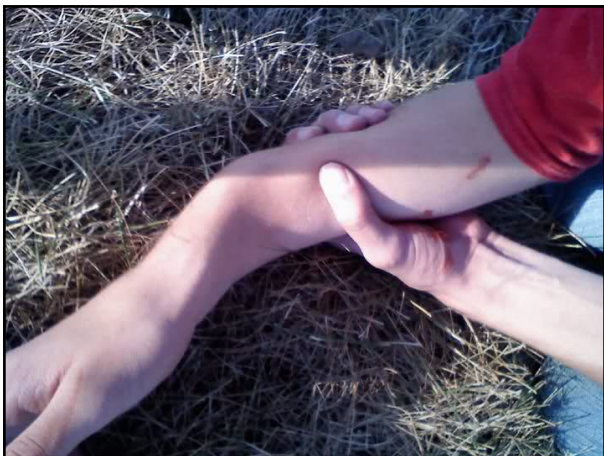28



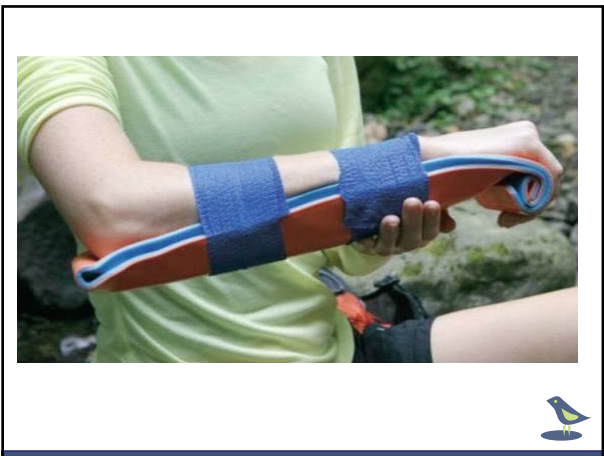29



30



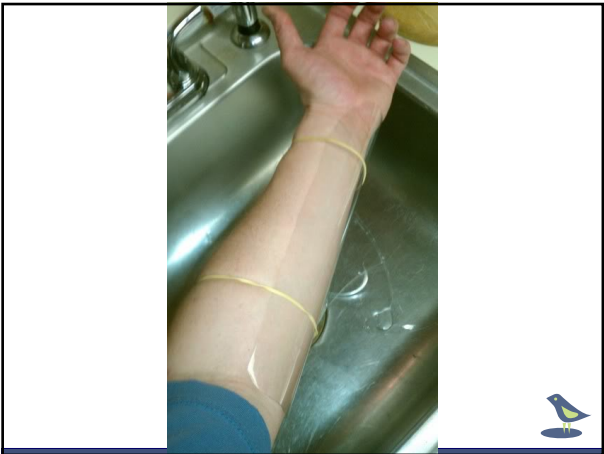31



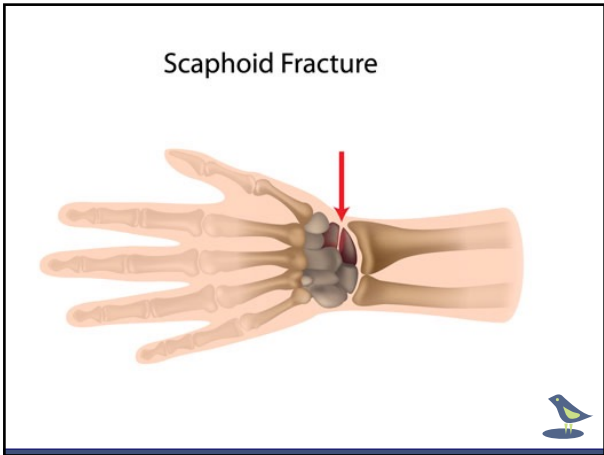
32



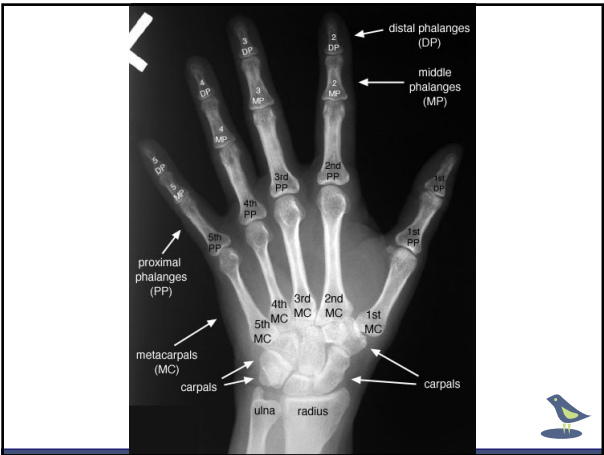33



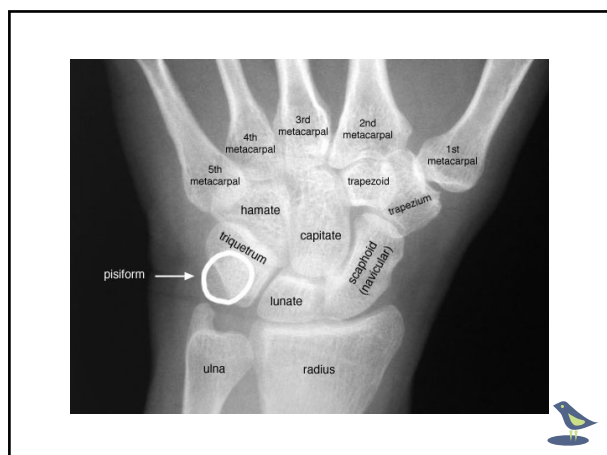
34



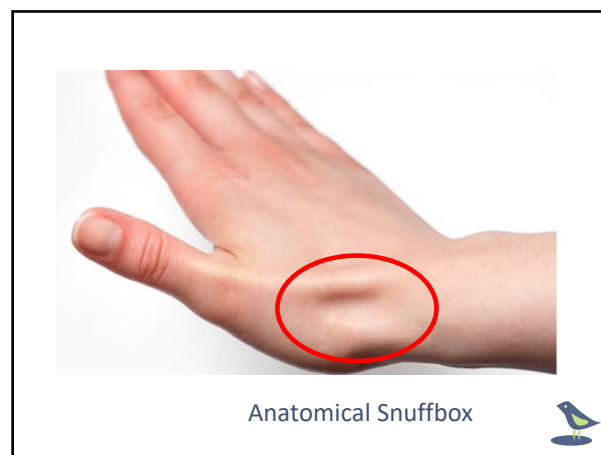35



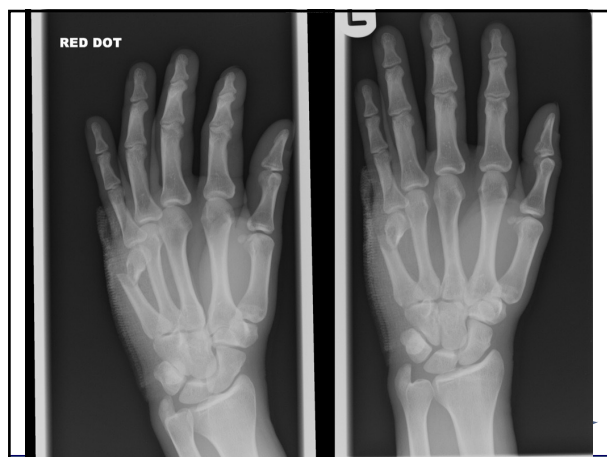
36



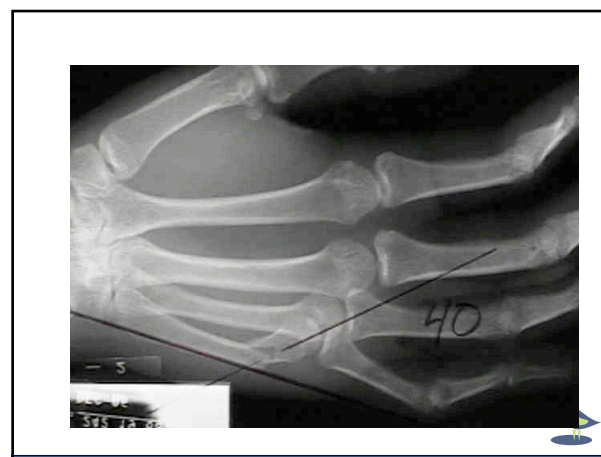37



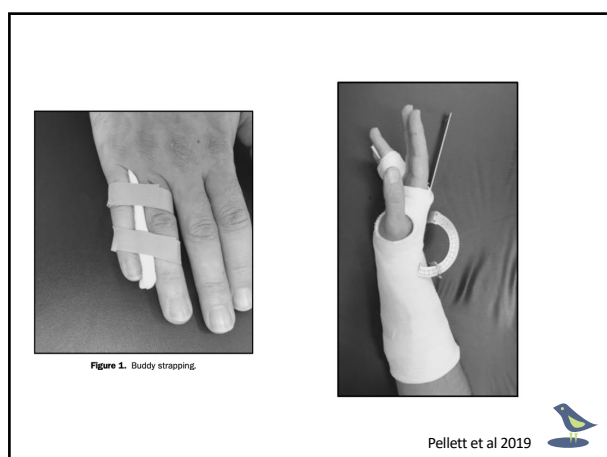
38



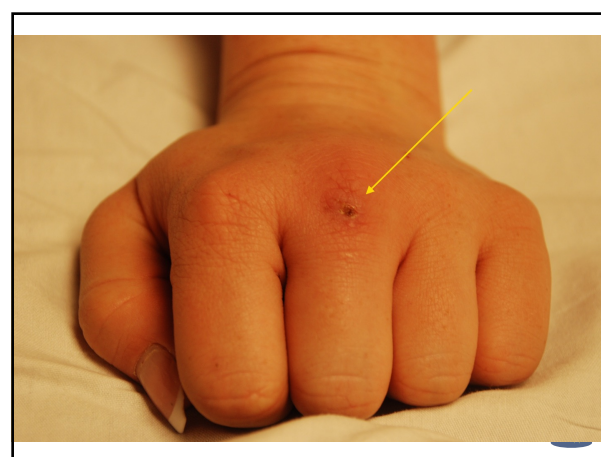
39



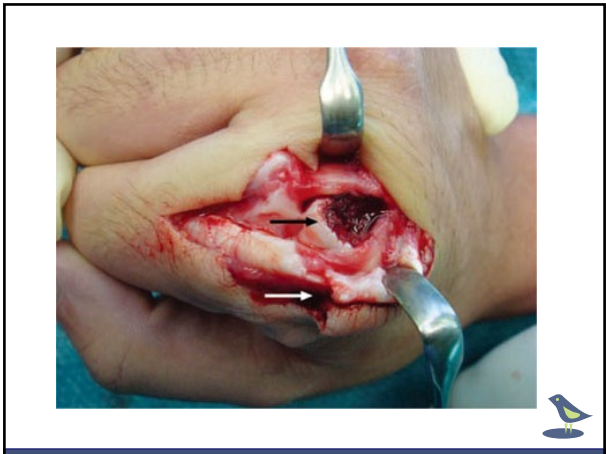40



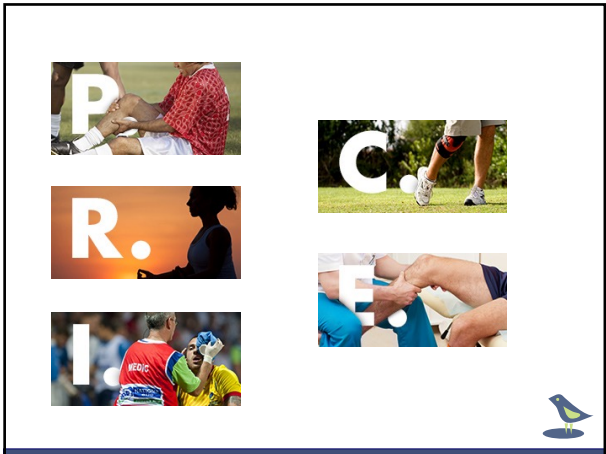
41




42



43



44



45